

MIDWEST DENTAL IMPLANTOLOGY

Tricia Crosby, DDS, MS | Martin Kolinski, DDS | William Trahan, DMD, MSD

Dentist With a Heart

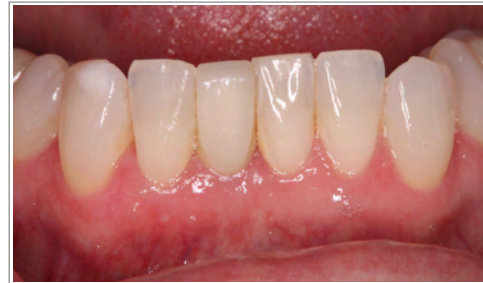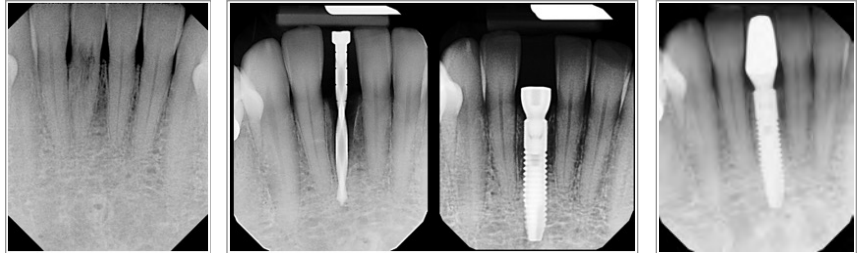
2017 will mark the 16th anniversary of Dentist with a Heart. This program involves opening your office one day in February to offer free dental services to those in need. You may select a date and time in February that works for you and your staff. The deadline is fast approaching! If your office is located in Kane, Kendall or Dekalb county and you would like to participate please contact Alexa Poulos at 630.377.4677.

Fall Dentist Seminar

Due to popular demand we have added a 5th date to our referring dentist seminar. It will be held on Wednesday, January 4th at our office from 5 - 7:30 pm. Please RSVP to Alexa Poulos at 630.377.4677.

Staff and Hygiene Seminar 2016

2016 marked the 2nd year of our annual Staff Seminar and the 9th year of our annual Hygiene Seminar. Including both seminars, we had a great turnout with over 150 dental staff and hygienists. Thank you to everyone that attended and for your commitment to excellence.



Immediate Implants

Placement of dental implants has become a preferred choice for tooth replacement; however, there are still a few obstacles that keep patients from accepting treatment. Time is one of these obstacles.

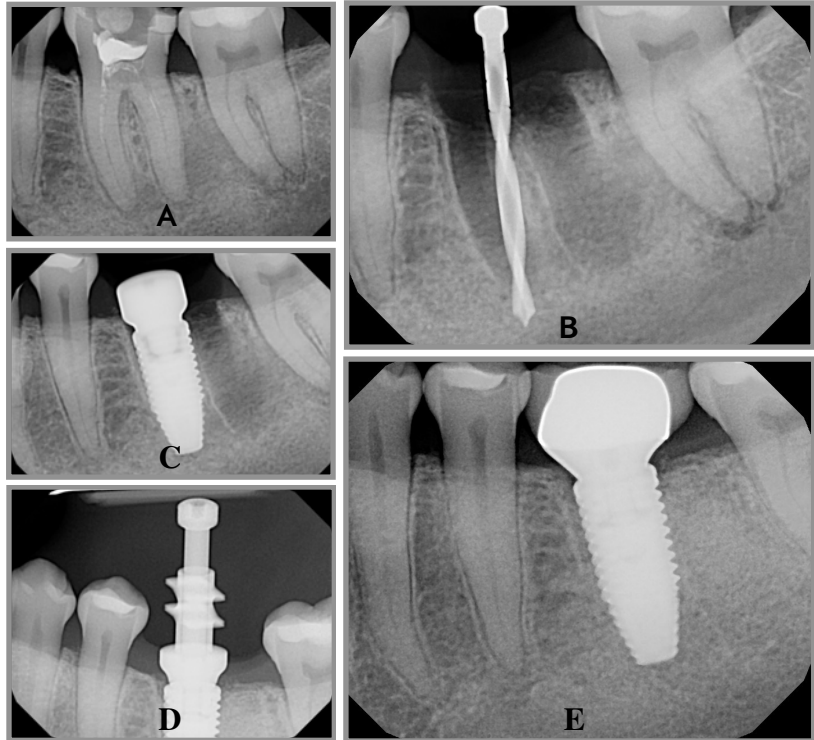
Traditionally, a patient might wait **8-12 months** from tooth extraction to final restoration. Immediate implants can shorten treatment time by placing the implant at the time of extraction and thus **avoiding a second surgical procedure.**

This means that that total treatment time could be shortened to **3-5 months.** Many times a fixed temporary can be placed that day or the next day. *Please call us for details.*

Our team aims to reduce the number of procedures necessary for your patient while striving to achieve an ideal esthetic result. Following a thorough examination which includes 3-D imaging, we are able to evaluate if this one phased treatment is appropriate for your patient. In the next section we highlight a couple cases demonstrating how this immediate approach can be beneficial to your patients.

Immediate Implants in Molar Sites

Mandibular molar sites can line up quite nicely for extraction and immediate implant placement. To the right is an example of such a case. The patient presented with a vertically fractured tooth #19 (A). The tooth was extracted using a minimally invasive technique. An implant was placed and the residual socket grafted, all in one visit (B,C). Following 3 months of healing, an open tray impression was taken (D). The final crown was delivered 4 months after the extraction (E).



Immediate Implants in Anterior Sites

Losing a front tooth can be a traumatic event, which is why replacing it as efficiently as possible is our top priority. To the right is an example of an emergency patient with a fractured lateral incisor (A,B). Extraction, immediate implant, and placement of an immediate screw-retained provisional (lab made) was completed. The implant was then allowed to integrate for 3 months (C,D,E).

Immediate provisionals have been shown to preserve natural soft tissue contours as well as provide immediate esthetics for the patient.

