



# Excellence Through Education

Spring 2011 Newsletter

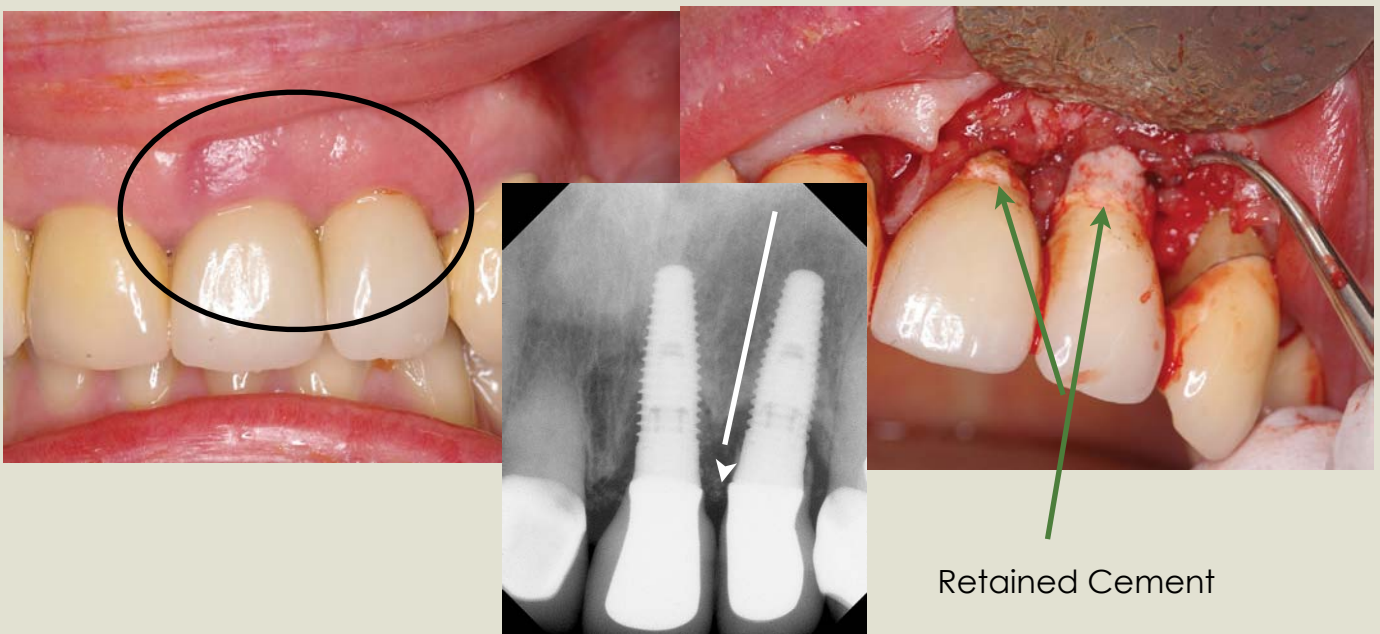
Martin L. Kolinski, DDS and Tricia R. Crosby, DDS, MS

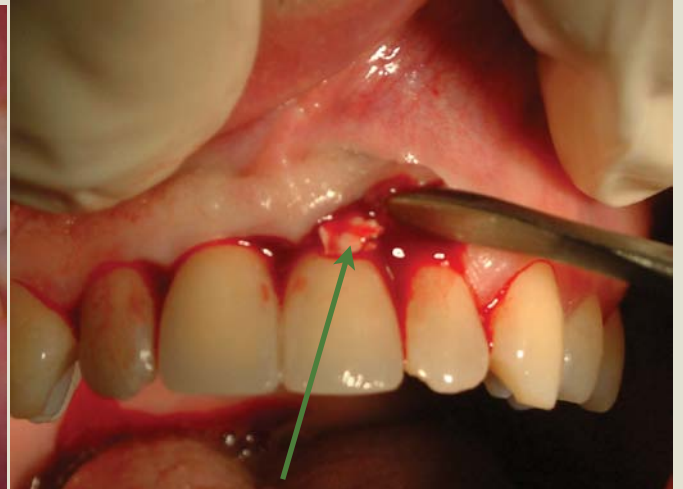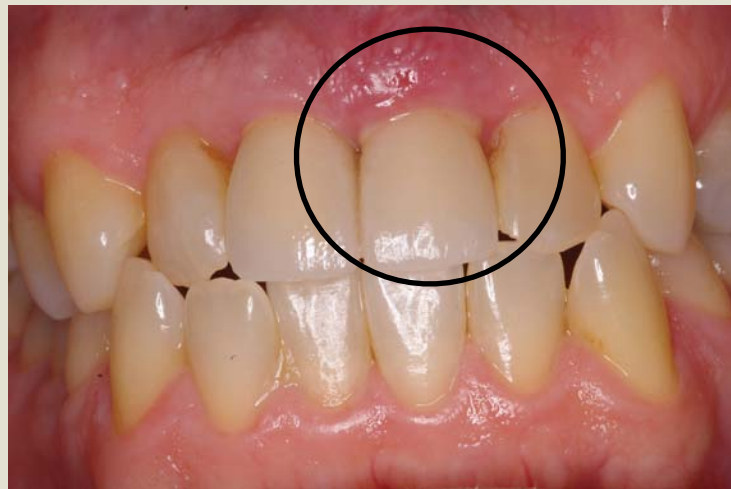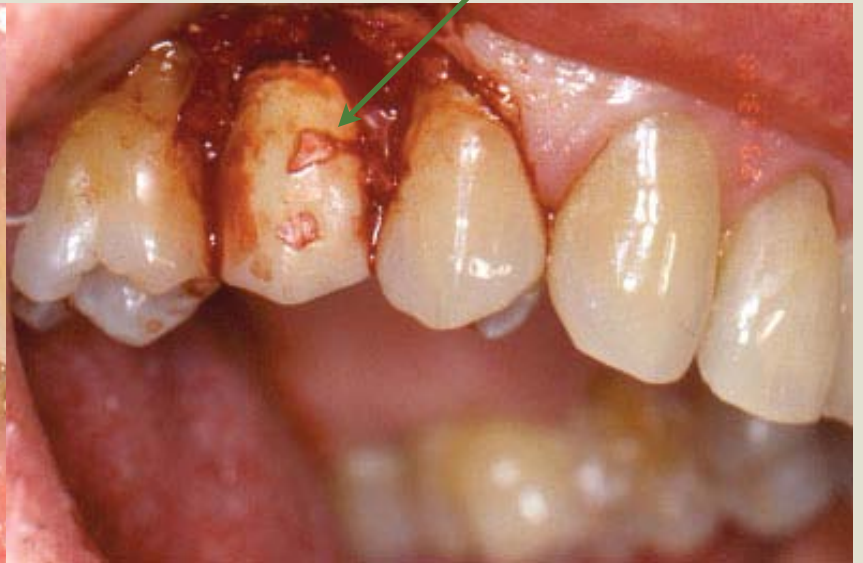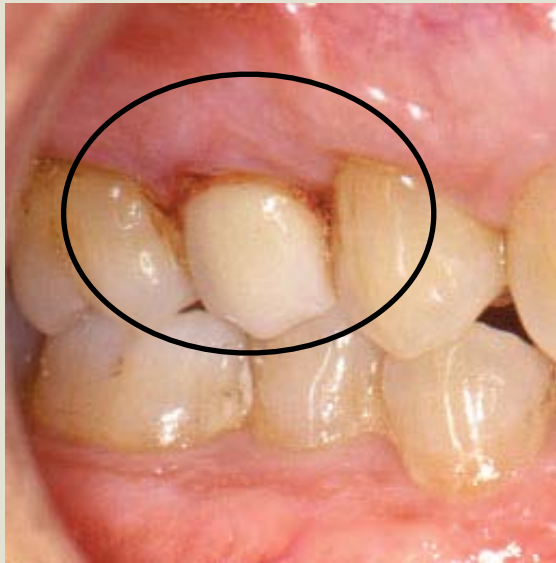## Technique for Controlling the Cement for an Implant Crown

Implant abutment/crown margins are typically subgingival, which poses a significant challenge when trying to remove excess cement following crown cementation to the implant abutment. This may be compounded by the fact that the peri-implant tissues are tightly adapted to the newly placed implant crown, making it difficult to negotiate the subgingival area.

The attached article offers a good approach to controlling excess cement flow into the subgingival tissues. **This article will also be posted on our website.**

***Please visit our website [midwestdentimplantology.com](http://midwestdentimplantology.com) for updates on our upcoming seminars.***





Retained Cement



# Technique for controlling the cement for an implant crown

Chandur Wadhvani, BDS, MSD,<sup>a</sup> and Alfonso Piñeyro, DDS<sup>b</sup>  
School of Dentistry, University of Washington, Seattle, Wash

Cementation of an implant prosthesis is an accepted protocol. Less demanding surgical placement of the implant, simpler laboratory techniques, passive fit, esthetics, and control of the occlusion are among some of the advantages.<sup>1</sup> However, disadvantages include unpredictable retention and resistance and the detrimental effect of cement flow into the soft tissues that can be difficult to remove. The soft tissue attachment onto the implant surface is more delicate than that seen at the natural tooth surface due to the lack of Sharpey fiber insertion, the reduced number of collagen fibers, and the direction in which these fibers run.<sup>2</sup>

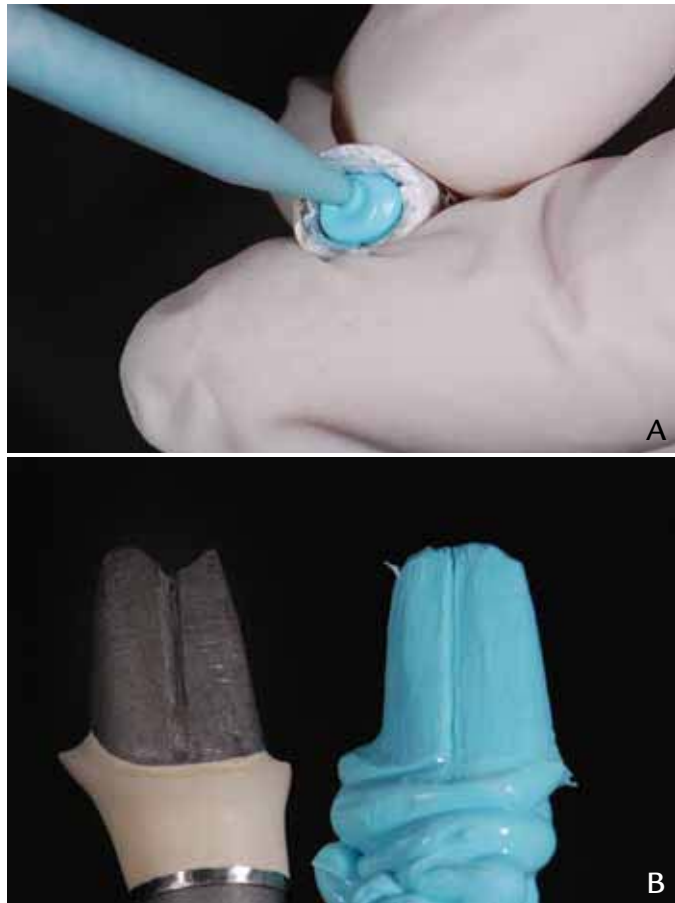
Cement extrusion into the sulcular area may result in soft tissue swelling, soreness, and bleeding or exudation on probing.<sup>3</sup> In some instances, the excess cement has been considered to be the cause of implant failure.<sup>4</sup> Removal of excess cement with plastic and metal scalers may result in scratches and gouges on the implant surfaces.<sup>5</sup>

Control of cement volume has been documented previously using the ITI solid abutment (Straumann USA, Andover, Mass).<sup>6</sup> This requires an implant analog or practice abutment, as described by the authors.<sup>6</sup> When a custom abutment is to be used under the crown, this becomes more challenging. The dental laboratory may be instructed to make a duplicate analog using an acrylic resin, but this is time consuming for the technician and involves additional laboratory costs.

A method of controlling cement flow using a copy abutment with smaller dimensions, which can be quickly, easily, and economically fabricated at the time of implant abutment/crown insertion, is described. The use of polytetrafluoroethylene (PTFE) tape provides a space of approximately 50  $\mu\text{m}$ , which represents the cement space and may be used for both custom and prefabricated abutments.

## PROCEDURE

1. Ensure fit of implant restoration and abutment complex.
2. Line the intaglio surface of the implant restoration with polytetrafluoroethylene (PTFE) tape, commonly known as Teflon tape, plumber's tape, or TFE (tetrafluoroethylene) threaded seal tape (Oatey Co, Cleveland, Ohio).
3. Place the implant restoration



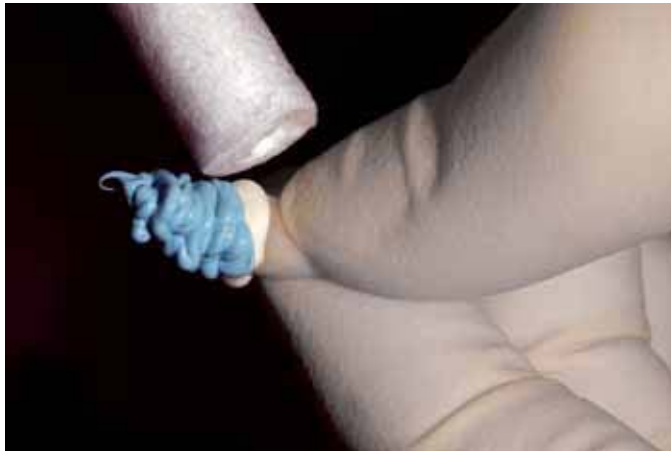**1** A, Fill intaglio of restoration with VPS material using smaller diameter tip. B, Compare and contrast abutment to VPS copy; in particular, irregularities should be noted as additional cement should be added to compensate for voids.

<sup>a</sup>Part-time Affiliate Faculty, Department of Restorative Dentistry; private practice, Bellevue, Wash.

<sup>b</sup>Part-time Affiliate Faculty, Department of Restorative Dentistry; private practice, Bellevue, Wash.

(J Prosthet Dent 2009;102:57-58)





**2** Remove excess cement once implant restoration is completely seated onto VPS abutment.

completely onto the abutment to facilitate the adaptation of the PTFE tape to the intaglio surface of the implant restoration.

4. Using a fast-setting vinyl polysiloxane (VPS) (Blu-Mousse Super-Fast; Parkell, Inc, Edgewood, NY) and an applicator with a smaller diameter tip, completely fill the implant restoration and form a handle (Fig. 1, A).

5. Remove the VPS material along with the PTFE and compare the implant abutment to the VPS model; ensure that no voids are present and that the abutment finish line has been accurately duplicated (Fig. 1, B).

6. Use the luting agent of choice (TempoCem; DMG, Hamburg, Germany) and line the intaglio of the implant restoration, then place the crown onto the VPS model and wipe off the excess cement before the cement has exceeded its working time (Fig. 2).

7. Remove the crown from the VPS model (there will be a layer of residual cement on the VPS model), and add a thin layer of cement in the intaglio of the restoration. If any voids are present, add a small amount of extra luting agent to fill the voids.

8. Place the implant restoration onto the implant abutment intraorally. Note that there should be little or no excess cement.

## REFERENCES

1. Hebel KS, Gajjar RC. Cement-retained versus screw-retained implant restorations: achieving optimal occlusion and esthetics in implant dentistry. *J Prosthet Dent* 1997;77:28-35.
2. Salvi GE, Lang NP. Diagnostic parameters for monitoring peri-implant conditions. *Int J Oral Maxillofac Implants* 2004;19 Suppl:116-27.
3. Pauletto N, Lahliff BJ, Walton JN. Complications associated with excess cement around crowns on osseointegrated implants: a clinical report. *Int J Oral Maxillofac Implants* 1999;14:865-8.
4. Gapski R, Neugeboren N, Pemeaz AZ, Reissner MW. Endosseous implant failure influenced by crown cementation: a clinical case report. *Int J Oral Maxillofac Implants* 2008;23:943-6.
5. Agar JR, Cameron SM, Hughbanks JC, Parker MH. Cement removal from restorations luted to titanium abutments with simulated subgingival margins. *J Prosthet Dent* 1997;78:43-7.
6. Dumbrigue HB, Abanomi AA, Cheng LL. Techniques to minimize excess luting agent in cement-retained implant restorations. *J Prosthet Dent* 2002;87:112-4.

### Corresponding author:

Dr C.P.K. Wadhvani  
1200 116<sup>th</sup> Ave NE, Ste A  
Bellevue, WA 98004  
Fax: 425-462-1878  
E-mail: cpkw@u.washington.edu

Copyright © 2009 by the Editorial Council for  
The Journal of Prosthetic Dentistry.

## Availability of Journal Back Issues

As a service to our subscribers, copies of back issues of The Journal of Prosthetic Dentistry for the preceding 5 years are maintained and are available for purchase from Elsevier Inc until inventory is depleted. Please write to Elsevier Inc, Subscription Customer Service, 6277 Sea Harbor Dr, Orlando, FL 32887, or call 800-654-2452 or 407-345-4000 for information on availability of particular issues and prices.